

Functional and structural imaging of pain-induced neuroplasticity

Frank Seifert and Christian Maihöfner

Department of Neurology, University of Erlangen-Nuremberg, Erlangen, Germany

Correspondence to Christian Maihöfner, MD, PhD, Department of Neurology, University of Erlangen-Nuremberg, Schwabachanlage 6, D-91054 Erlangen, Germany
Tel: +49 9131 853 3001; fax: +49 9131 854 2497; e-mail: christian.maihofner@uk-erlangen.de

Current Opinion in Anesthesiology 2011, 24:515–523

Purpose of review

The understanding of the mechanisms underlying chronic pain is of major scientific and clinical interest. This review focuses on neuroimaging studies of pain-induced neuroplastic changes in the human brain and discusses five major categories of pain-induced neuroplastic changes.

Recent findings

First, peripheral or central sensitization may result in increased nociceptive input to the brain and also changes the processing of nociceptive information within the brain. Second, chronic nociceptive input from the periphery or from lesions within the central nervous system may result in cortical reorganization and maladaptive neuroplasticity within somatosensory and motor systems. Thirdly, there is evidence for pain-induced changes in large-scale neuronal network connectivity. Fourth, in patients with chronic pain, structural brain changes may occur. Finally, there is discussion that in chronic pain patients the endogenous pain-modulatory system may function aberrantly.

Summary

Recent work has substantially broadened our insights into neuroplastic changes that are involved in pain chronification. Future research will focus on the question of whether neuroimaging techniques can be used in the individual chronic pain patient as a biomarker that would allow for an objective diagnosis of different pain conditions and for the prediction of individual responses to specific therapies.

Keywords

central sensitization, cortical reorganization, endogenous pain control system, functional magnetic resonance imaging, functional imaging, neuropathic pain, pain, resting state connectivity, voxel-based morphometry

Curr Opin Anesthesiol 24:515–523
© 2011 Wolters Kluwer Health | Lippincott Williams & Wilkins
0952-7907

Introduction

Chronic pain is a major health problem, affecting approximately 19% of the entire population in the Western world [1]. In the last two decades, noninvasive functional and structural neuroimaging methods have enabled rapid progress in understanding the processing of pain in the human brain and have provided insight into the previously unknown mechanisms underlying pain chronification [2,3]. Since the first PET study, investigating brain areas activated by painful thermal stimulation [4], a well defined set of brain areas involved in pain processing has been identified [3,5^{*},6,7]. The modulation of pain by cognitive and emotional processes and the underlying brain mechanisms are increasingly understood [8]. Moreover, it has been clearly demonstrated that ongoing noxious signalling to the central nervous system leads to neuroplastic changes in the brain [2,3], which generate and maintain the chronification of pain. Advanced structural imaging methods even revealed macroscopic changes in the brain morphology of chronic pain patients [9]. Now, research in the neuroimaging field

goes beyond simple activation studies and begins to focus on functional and structural brain network connectivity. In the following, we will briefly describe major neuroimaging methods and we will give an overview on pain processing in the human brain. We will then review neuroimaging work on brain plastic changes at the systems level that underlie the transition from acute to chronic pain. We will focus on pain-induced plastic changes that result in altered activity in the pain neuro-matrix, pain-induced cortical reorganization and maladaptive neuroplasticity, altered resting state-network or task-network connectivity in patients with chronic pain, and pain-induced structural brain changes. Furthermore, we will discuss the possibility that endogenous pain-modulatory systems function aberrantly in patients with chronic pain.

Neuroimaging methods

There are three different main techniques for functional brain imaging: PET, functional MRI (fMRI) and magnetoencephalography (MEG). These techniques differ

in their invasiveness and temporal and spatial resolution. fMRI and PET do not assess the activity of neurons directly, but instead measure metabolic and vascular changes as a downstream effect of neuronal activity.

PET uses radioactive tracers injected into the bloodstream, which then accumulate in activated brain regions. Depending on the tracer, regional cerebral blood flow (rCBF) or consumption of oxygen or glucose can be assessed. PET has been used in particular to explore the brain activity induced by spontaneous pain [10,11], because in contrast to fMRI, PET allows the measurement of the basal brain activity.

fMRI uses gradient echo sequences sensitive to the amount of deoxyhaemoglobin in the blood. Deoxyhaemoglobin has strong paramagnetic properties and introduces distortions to the local magnetic field. These distortions can be measured and indicate the local ratio between oxyhaemoglobin and deoxyhaemoglobin. This technique has been termed blood oxygenation level dependent (BOLD) imaging. In the classical task-fMRI, the stimuli (e.g. pain stimuli) are applied in blocks (block design) or as repetitive single-events (event-related design), alternating with a baseline condition. This extensively used approach has resulted in brain activation maps displaying brain areas activated or deactivated by pain, for review see [6]. More recently, functional connectivity MRI has evolved. This method correlates either the BOLD signal time course extracted from a defined brain region with the signal time course in each of the other voxels of the recorded brain volume or uses data-driven approaches (e.g. independent component analysis). Functional connectivity MRI can be performed on data acquired during stimulus presentation, task performance or in the resting state. Areas with correlating BOLD signal time courses are considered to be functionally connected. Performed in the resting state (in which the patient lies with closed eyes in the scanner and is instructed to think about nothing in particular), this approach uses spontaneous low-frequency BOLD fluctuations that correlate between brain areas belonging to specific functional networks, the so-called resting state networks. The first results suggest that the spatial or temporal properties of these networks may be altered in pain states [12^{••},13[•],14,15].

MEG provides an excellent temporal and spatial resolution. Electrical currents of neurons produce a magnetic field which can be measured at the skull. MEG is mainly limited to the investigations of superficial cortical regions, as it is difficult to detect magnetic fields emanating from deeper brain regions.

Finally, advanced structural neuroimaging methods are voxel-based morphometry (VBM) and diffusion

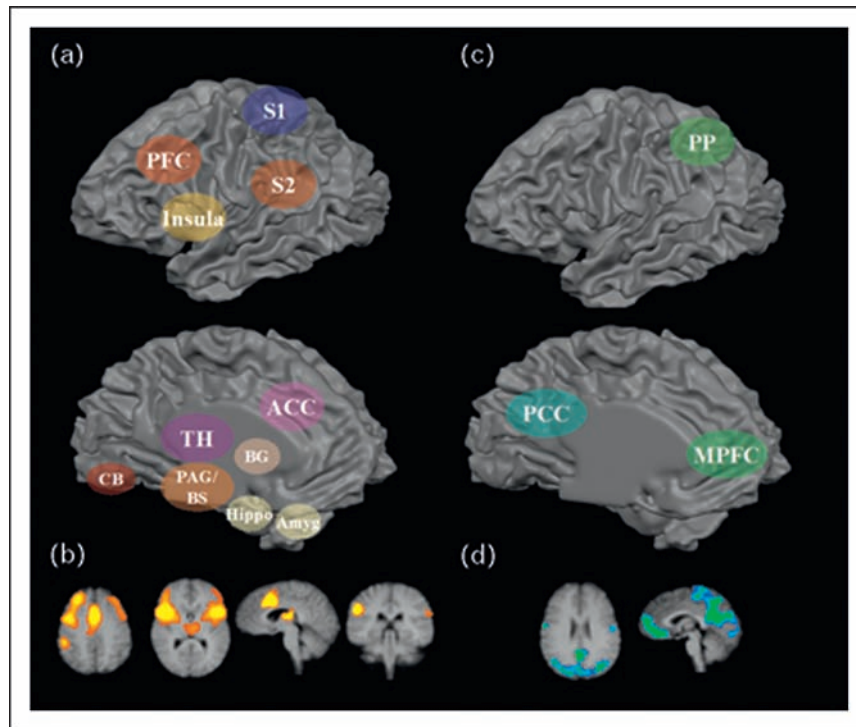
Key points

- Increased nociceptive input to the brain induces neuroplastic changes within the nociceptive system which underlie the transition to and maintenance of chronic pain.
- Chronic nociceptive input to the brain results in cortical reorganization and maladaptive neuroplasticity within somatosensory and motor systems.
- Chronic pain is associated with temporal and spatial changes in large-scale neuronal network connectivity.
- Chronic pain leads to macroscopic structural brain changes.

tensor imaging (DTI). VBM measures cortical thickness or subcortical grey matter volume. However, it is still not clear which cellular mechanisms underlie such macroscopic morphologic changes (e.g. local change in the number of synapses, neurons, glia or blood vessels) [9]. DTI allows visualization of white-matter tracts by measuring local fractional anisotropy and can be used to collect information on structural connectivity.

Processing of acute and chronic pain in the human brain

Noxious stimuli usually activate nociceptive nerve endings. These so-called nociceptors project to dorsal horn neurons located mainly in laminae I, II and V, which in turn project to thalamic neurons in the nucleus ventralis posterior medialis and lateralis and also to the medial thalamus. From there, thalamocortical pathways target the primary (S1) and secondary (S2) somatosensory cortex, the insula, anterior cingulate gyrus (ACC), the prefrontal cortex (PFC) and the parietal association cortex. These brain areas are often referred to as the 'neuronal matrix' [16] of pain. Nevertheless, it should be emphasized that similar networks are also activated during a great variety of different potentially threatening stimuli [17–19]. fMRI and PET activation studies contributed significantly to the knowledge on processing of pain in the human brain in health and disease. Early studies focused mainly on the processing of acute pain. From these studies, there is accumulating evidence that these areas process different aspects of pain [20–23]. The results suggest that the nociceptive input into posterior insula and primary and secondary somatosensory cortices, the so-called 'lateral pain system', underlies the perception of sensory-discriminative features of pain. In contrast, ACC, PFC and parts of the insula, the so-called 'medial pain system', have been implicated in the affective-motivational processing of pain [24–27]. Prefrontal cortical areas may also be related to cognitive variables, such as memory or stimulus evaluation [6].

Figure 1 Brain areas involved in pain processing

(a) Schematic illustration of areas activated by pain. (b) Corresponding functional MRI (fMRI) activations. (c) Schematic illustration of areas deactivated by pain. (d) Corresponding fMRI deactivations. ACC, anterior cingulate gyrus; BG, basal ganglia; BS, brainstem; CB, cerebellum; MPFC, medial prefrontal cortex; PP, posterior parietal cortex; PCC, posterior cingulate cortex; PFC, prefrontal cortex; S1, primary somatosensory cortex; S2, secondary somatosensory cortex; TH, thalamus.

The brain network activated by painful stimuli is depicted in Fig. 1.

Importantly, it has been shown that the nociceptive system is not hard wired but instead shows remarkably functional and structural plasticity [28,29]. Plastic changes may occur at the peripheral level with increased responsiveness of nociceptors or recruitment of previously silent nociceptors, a mechanism called peripheral sensitization. Tissue damage, inflammation or peripheral nerve damage may result in increased nociceptive signaling to the central nervous system. Increased nociceptive input into the dorsal horn, with or without the presence of peripheral sensitization, results in changes in the synaptic transmission within the spinal cord itself. This mechanism is called central sensitization. Both mechanisms, peripheral sensitization at the nociceptor level and central sensitization at the spinal level, may result in augmented and ongoing nociceptive input to the brain which may lead to specific brain activation patterns during these pathological chronic pain states. Permanent activity in the nociceptive system can result in functional and structural alterations in the 'pain neuromatrix' and in other brain networks involved in somatosensory, motor, attentional and emotional processing.

Altered activity because of neuroplastic changes in the pain neuromatrix

Basically, tissue damage and inflammation lead to sensitization of nociceptive nerve endings located in the affected tissue. The sensitized nociceptors may lower their activation threshold, become spontaneously active and increase their response to noxious stimuli. Alternatively, peripheral nociceptive neurons may become spontaneously active because of peripheral nerve injury. In both cases, the resulting increase in nociceptive input to the spinal cord may in turn alter the synaptic transmission at the spinal level, thus inducing central sensitization. In the presence of peripheral or central sensitization, the areas of the pain neuromatrix are activated differentially [5^o,30,31]. Importantly, there is no simple leftward shift of the stimulus response curve in the areas of the pain neuromatrix induced by a spinal gain in the transmission of nociceptive signalling: using PET, it has been shown that during central sensitization intensity-matched heat pain stimuli were more unpleasant and activated the PFC, ACC and medial thalamus to a significantly stronger degree [32]. These areas are involved in the processing of the affective-motivational component of pain. On the other hand, it has been shown

that the sensory-discriminative aspects of central sensitization, that is, increased perception of pain intensity, are mediated by the somatosensory cortex [33].

In patients with clinical chronic pain, we can distinguish between studies that investigated spontaneous ongoing and stimulus evoked pain. In patients with spontaneous ongoing neuropathic pain, PET studies revealed a consistent reduction in rCBF in the contralateral thalamus [10,11] but an increased rCBF in insula, ACC, parietal association cortex and PFC [10]. As an explanation for the thalamic rCBF decrease, thalamic neuroplastic changes have been discussed [11]. Elaborated fMRI design with percept-related regressors have been used to explore brain activity during different phases of spontaneous pain in patients with chronic back pain [34]. During phases of high spontaneous pain, increased activity was detected in the PFC and ACC. However, in phases of increasing pain, an activation of the classical pain neuromatrix was found. These findings suggest that the subjective spontaneous pain of chronic ongoing pain involves distinct spatiotemporal neuronal mechanisms differing from those observed during acute experimental pain [34].

Cerebral processing of stimulus-evoked pain has been explored in patients with neuropathic pain [3,6,7,26,35]. During dynamic mechanical allodynia in neuropathic pain, activations were predominantly detected in the lateral pain system, whereas ACC was not consistently activated [36–42]. During pin-prick hyperalgesia in complex regional pain syndrome (CRPS) patients, increased activity was detected in all areas of the pain neuromatrix and regions associated with motor or cognitive processing, that is, PFC and motor cortices [43]. Thermal hyperalgesia as a symptom of neuropathic pain was investigated by another fMRI study: during cold allodynia, compared with dynamic tactile allodynia, the PFC was the only area consistently activated by both types of pathologically evoked pain, suggesting that alteration of high-level pain-modulatory mechanisms might play a major role [41].

Cortical reorganization and maladaptive neuroplasticity beyond the pain neuromatrix

Chronic noxious input to the brain results in neuroplastic changes beyond the nociceptive system. Patients with some forms of chronic pain present with symptoms that can only be explained by an involvement of central somatosensory or motor systems. Such conditions are especially common in phantom pain, neuropathic pain after spinal cord injury (SCI) and CRPS. Central changes within the somatosensory system have also been shown for diseases like carpal tunnel syndrome [44,45].

Phantom pain mainly occurs after extremity amputations. Pain in the nonexistent body part develops in 50–80% of

all amputees [46]. Underlying mechanisms in the periphery include pathological sympathico-afferent coupling and ectopic discharges within the stump neuroma [46,47]. As demonstrated with MEG source imaging, the mouth area of S1 was found to be shifted into that of the former hand [48–50]. Interestingly, the extent of this shift was highly correlated with the intensity of phantom limb pain [49]. It was suggested that ongoing nociceptive input before amputation induces neuroplastic changes and leads to organization of a pain memory, with nociceptive input from neighbouring regions into the deafferented area after amputation resulting in phantom pain [46,47]. This is supported by a study showing that the presence of preamputation pain is positively correlated with the presence of phantom limb pain 3 months after amputation [51]. The neuroplastic changes are reversible. Cortical reorganization can be reduced by behaviourally relevant sensory discrimination training in the stump area [52]. Reorganization of somatotopic maps in phantom limb pain was also found in the primary motor cortex, where, similar to the changes in S1, the mouth area shifts into that of the former hand [53]. The use of a myoelectric prosthesis is accompanied by the reduction of phantom pain and cortical reorganization [53].

Spinal cord injury (SCI) leads to sensorimotor loss below the lesion. Many patients with SCI also develop neuropathic pain below the injury. In these patients, S1 reorganization was demonstrated with the little-finger representation moving medially towards the S1 region that would normally innervate the legs. The amount of S1 reorganization significantly correlated with ongoing pain intensity levels [54]. Extending these findings, SCI was associated with grey matter volume loss in the lower body representation; however, this loss was minimized as reorganization increased [55[•]]. The medial shift in little-finger representation correlated positively with grey matter preservation in lower body representation [55[•]]. Moreover, in the D5 representation area fractional anisotropy was correlated with S1 reorganization. Thus, as S1 reorganization increased, the extent of aligned structures decreased and the direction of water movement within the D5 representation was directed more toward the midline [55[•]]. The authors conclude that S1 reorganization in humans results from the growth of new lateral connections, and not simply from the unmasking of already existing lateral connections [55[•]].

CRPS develops after trauma and is defined by the occurrence of pain accompanied by sensory, motor and autonomic changes beyond the territory of a single peripheral nerve [56]. In addition to facilitated neurogenic inflammation in the affected tissue, there is mounting evidence that central nervous system changes may be involved in the pathogenesis of CRPS [56,57]. Regarding the somatosensory system, there is evidence for a

substantial reorganization of the somatotopic map within the primary somatosensory cortex of CRPS patients [57–62]. Functional imaging techniques demonstrated a shrinkage of the cortical hand representation contralateral to the arm affected by CRPS [57,59,61]. In addition, the hand position was shifted towards the mouth. Predictors for this cortical reorganization were spontaneous CRPS pain and the extent of mechanical hyperalgesia. When treatment is efficacious and CRPS pain reduced, this S1 cortical reorganization in CRPS patients can be reversed [59,61]. Cortical reorganization in CRPS is illustrated in Fig. 2.

Maladaptive neuroplasticity may be able to explain some of the puzzling clinical signs of CRPS, for example, the spatial distribution of sensory disturbances in a glove or stocking like distribution, the occurrence of tactilely induced referred sensations [60] and hemisensory deficits [63,64]. Furthermore, there is evidence that the central motor system in CRPS patients is altered. Many patients with CRPS present a weakness of the affected limb [62,65]. Other symptoms include movement disorders like dystonia, tremor and myoclonus [66]. Additionally, a neglect-like syndrome may lead to the disuse of the limb [62,67]. Studies using MEG or transcranial magnetic stimulation revealed a deficiency of inhibitory mechanisms and an increased excitability of the contralateral and ipsilateral primary motor cortex in CRPS patients [58,68,69]. Our group investigated cortical activations during tapping movements of the CRPS-affected hand [62]. During finger tapping of the affected hand, CRPS

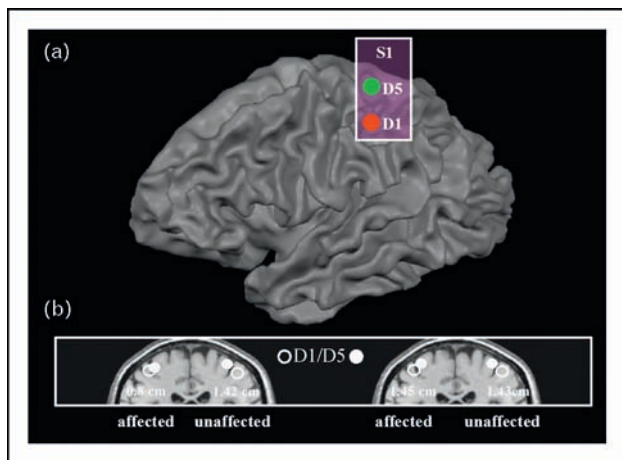
patients showed a significant reorganization of central motor circuits, with an increased activation of primary motor and supplementary motor cortices (SMA) and a markedly increased activation of the ipsilateral motor cortex. Abnormal activations of the posterior parietal cortices, SMA and primary motor cortex correlated with the extent of motor dysfunction. The results show substantial adaptive changes within the central nervous system that may underlie motor dysfunction in CRPS.

Carpal tunnel syndrome (CTS) is an entrapment neuropathy of the median nerve characterized by paresthesia and pain in the median nerve territory. Although CTS is a classical peripheral nerve lesion, it is accompanied by central nervous changes. MEG and fMRI studies found that CTS patients have changes in cortical hand somatotopy that can be reversed by treatment [44,45,70].

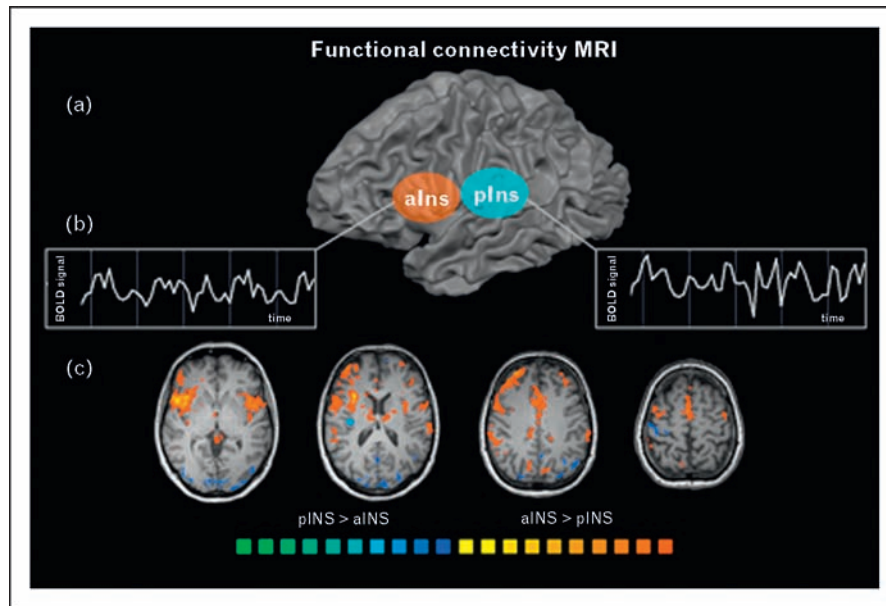
Alterations of network connectivity

During the previous years, functional connectivity MRI has evolved [71–74]. Performed in the resting state, this method uses spontaneous, low-frequency BOLD fluctuations in specific functional networks, the so-called resting state networks. There are results indicating that the spatial or temporal properties of these networks may be altered in pain states. Baliki *et al.* [15] studied a group of chronic back pain patients and healthy controls while executing a simple visual attention task and found that the patients displayed reduced deactivation in several key regions of the default mode network. The authors suggested that these findings display disruptions of the default mode network which may underlie the cognitive and behavioural impairments accompanying chronic pain [15]. Several later studies corroborated these findings by describing altered default mode networks, altered resting state attentional networks and altered thalamocortical connectivity in patients with chronic pain because of diabetic neuropathy [13[•],14,75]. Another study reported aberrant temporal and spatial brain activity during rest in patients with chronic pain [12^{••}]. The time courses of the insular cortices of both hemispheres showed stronger spectral power at 0.12–0.25 Hz in patients than in control individuals, whereas the control sites (visual areas) did not differ between the groups. Moreover, in patients an altered spatial connectivity between bilateral insular cortex and anterior cingulate cortex was detected [12^{••}]. Other research focused on altered network connectivity during pain stimuli in chronic pain patients [76^{••}], on the influence of prestimulus functional connectivity on pain perception [77[•]], and on functional connectivity of different insular subregions during noxious stimulation [78[•]] (Fig. 3). Future studies will further illuminate how the spatial and temporal dimensions of brain network connectivity change during pain chronification.

Figure 2 This figure depicts cortical reorganization and maladaptive plasticity in patients with complex regional pain syndrome



(a) Schematic illustration of somatotopic arrangement in S1. (b) The distance between D1 and D5 in the contralateral somatosensory cortex (S1) is decreased in CRPS (left panel). After sufficient treatment of the CRPS these changes were reversed (right panel). Modified with permission from [59].

Figure 3 Functional connectivity of the insular cortex during painful thermal stimulation

(a) Schematic illustration of anterior (alns) and posterior (plns) insula on a reconstructed hemisphere. (b) Exemplary illustration of corresponding functional MRI signal time courses extracted from the anterior (left panel) and posterior (right panel) insular cortex. (c) Functional connectivity MRI. Areas with significantly more functional connectivity to the anterior insula are coded red–yellow; areas with significantly more functional connectivity to the posterior insula are coded blue–green. Modified with permission from [78*].

Structural brain changes

An increasing number of studies have reported macroscopic changes in grey matter volume in pain processing brain regions, for a recent review see [9]. The first VBM study on chronic pain patients investigated patients with chronic low back pain. A decrease in grey matter was measured at the global brain level and also regionally, in the bilateral PFC and right thalamus [79]. Grey matter decrease at the brain level correlated positively with disease duration and was pronounced in the dorsolateral prefrontal cortex (DLPFC) in a subgroup of neuropathic pain patients. Subsequent studies investigated patients with different types of chronic pain, for example, phantom pain [80], CRPS [81], pain after spinal cord injury [82], headache [83–87] and peripheral neuropathic pain [88]. These studies also found grey matter decreases in pain-related brain regions. In a recent study, patients with chronic pain because of primary hip osteoarthritis had a characteristic grey matter decrease in the ACC, right insula, DLPFC, amygdala and brainstem [89]. After surgery, patients were pain free, and this was accompanied by a grey matter increase in the DLPFC, ACC, amygdala and brainstem. Thus, the morphologic changes were reversed [89]. Another study found decreased thalamic grey matter in osteoarthritis patients, which was also reversed after surgery [90]. These findings indicate that the grey matter reduction during chronic pain is not an irreversible neurodegenerative mechanism.

Future work is required to elucidate the molecular and cellular mechanisms underlying these macroscopic changes.

Challenges for future research

It is well known that central pain-modulating systems may inhibit or facilitate nociceptive input. The periaqueductal grey (PAG) of the midbrain and the rostroventral medulla (RVM) are important nuclei of descending pain modulation. Descending pain modulation seems to play an important role in chronic pain states [91]. The mechanisms of how attentional, cognitive and emotional processes influence cerebral nociceptive processing have been illuminated by recent neuroimaging studies in healthy individuals [92–102], for detailed reviews see [8,103,104]. There is accumulating evidence that activity of endogenous pain modulatory systems may be defective in neuropathic pain, thus contributing to chronification [105–107]. Unfortunately, functional imaging studies investigating endogenous pain modulation in clinical pain states are not yet available. Therefore, future imaging studies are needed to address this exciting topic.

Future research will also focus on the question of whether neuroimaging can be used as a biomarker for diagnostic or mechanistic classification of different pain conditions in the individual chronic pain patient. These biomarkers

could potentially predict the individual response to specific therapeutic interventions. This implies the use of computational approaches to decode brain states from temporospatial fMRI activation patterns [108,109].

Finally, we have also begun to understand how pharmacological interventions change abnormal brain activity in neuropathic pain. This pharmacofMRI approach can be used to understand effects of analgesic and antihyperalgesic drugs in the human brain. Iannetti *et al.* [110] investigated the effects of gabapentin on capsaicin-induced mechanical hyperalgesia using fMRI. Gabapentin significantly reduced activations in bilateral operculoin-sular cortices. Furthermore, during central sensitization, gabapentin reduced the activation of brain stem structures and suppressed stimulus-induced deactivations. Maihöfner *et al.* [111] examined potential differential fMRI correlates of analgesic and antihyperalgesic effects of two intravenous cyclo-oxygenase (COX) inhibitors, that is, parecoxib and acetylsalicylic acid in the model of UV-B-induced hyperalgesia. The results of this study suggested a differential modulation of brain areas under either analgesia or antihyperalgesia. Modulation of prefrontal cortices was also demonstrated to be predictive for response to antihyperalgesic treatment with lidocaine (a sodium channel blocker) in the model of electrically induced secondary hyperalgesia [112]. Future studies will illustrate how we can use pharmacofMRI as an objective 'read out' to refine our pharmacological approaches to neuropathic pain.

Conclusion

Recent work has substantially broadened our insights into neuroplastic changes that are involved in pain chronification.

Acknowledgements

This work was supported by the German Research Network 'Neuropathic Pain' of the German Federal Ministry of Education and Research (Bundesministerium für Bildung und Forschung; BMBF), the German Research Foundation (Deutsche Forschungsgemeinschaft, KFO 130) and the ELAN-Fond of the University of Erlangen.

Conflicts of interest

There are no conflicts of interest.

References and recommended reading

Papers of particular interest, published within the annual period of review, have been highlighted as:

- of special interest
- of outstanding interest

Additional references related to this topic can also be found in the Current World Literature section in this issue (p. 594).

- 1 Breivik H, Collett B, Ventafridda V, *et al.* Survey of chronic pain in Europe: prevalence, impact on daily life, and treatment. *Eur J Pain* 2006; 10:287–333.
- 2 Apkarian AV, Hashmi JA, Baliki MN. Pain and the brain: specificity and plasticity of the brain in clinical chronic pain. *Pain* 2011; 152:S49–S64.
- 3 Seifert F, Maihöfner C. Central mechanisms of experimental and chronic neuropathic pain: findings from functional imaging studies. *Cell Mol Life Sci* 2009; 66:375–390.
- 4 Talbot JD, Marrett S, Evans AC, *et al.* Multiple representations of pain in human cerebral cortex. *Science* 1991; 251:1355–1358.
- 5 Lanz S, Seifert F, Maihöfner C. Brain activity associated with pain, hyperalgesia and allodynia: an ALE meta-analysis. *J Neural Transm* 2011. [Epub ahead of print]
- A recent quantitative meta-analysis of pain-related neuroimaging studies. This study shows distinct cerebral networks for nociceptive and neuropathic pain.
- 6 Apkarian AV, Bushnell MC, Treede RD, Zubieta JK. Human brain mechanisms of pain perception and regulation in health and disease. *Eur J Pain* 2005; 9:463–484.
- 7 Moisset X, Bouhassira D. Brain imaging of neuropathic pain. *Neuroimage* 2007; 37 (Suppl. 1):S80–S88.
- 8 Tracey I, Mantyh PW. The cerebral signature for pain perception and its modulation. *Neuron* 2007; 55:377–391.
- 9 May A. Structural brain imaging: a window into chronic pain. *Neuroscientist* 2011; 17:209–220.
- 10 Hsieh JC, Belfrage M, Stone-Elander S, *et al.* Central representation of chronic ongoing neuropathic pain studied by positron emission tomography. *Pain* 1995; 63:225–236.
- 11 Iadarola MJ, Max MB, Berman KF, *et al.* Unilateral decrease in thalamic activity observed with positron emission tomography in patients with chronic neuropathic pain. *Pain* 1995; 63:55–64.
- 12 Malinen S, Vartiainen N, Hlushchuk Y, *et al.* Aberrant temporal and spatial brain activity during rest in patients with chronic pain. *Proc Natl Acad Sci U S A* 2010; 107:6493–6497.
- This recent study of outstanding interest reported a frequency shift of spontaneous BOLD-fluctuations in the insular cortices of both hemispheres in patients with chronic pain.
- 13 Cauda F, D'Agata F, Sacco K, *et al.* Altered resting state attentional networks in diabetic neuropathic pain. *J Neurol Neurosurg Psychiatry* 2010; 81:806–811.
- The authors describe altered resting state attentional networks in diabetic neuropathic pain.
- 14 Cauda F, Sacco K, Duca S, *et al.* Altered resting state in diabetic neuropathic pain. *PLoS One* 2009; 4:e4542.
- 15 Baliki MN, Geha PY, Apkarian AV, Chialvo DR. Beyond feeling: chronic pain hurts the brain, disrupting the default-mode network dynamics. *J Neurosci* 2008; 28:1398–1403.
- 16 Melzack R. From the gate to the neuromatrix. *Pain* 1999; Suppl 6:S121–S126.
- 17 Iannetti GD, Mouraux A. From the neuromatrix to the pain matrix (and back). *Exp Brain Res* 2010; 205:1–12.
- 18 Mouraux A, Diukova A, Lee MC, *et al.* A multisensory investigation of the functional significance of the 'pain matrix'. *Neuroimage* 2011; 54:2237–2249.
- 19 Legrain V, Iannetti GD, Plaghki L, Mouraux A. The pain matrix reloaded: a salience detection system for the body. *Prog Neurobiol* 2011; 93:111–124.
- 20 Maihöfner C, Herzner B, Otto Handwerker H. Secondary somatosensory cortex is important for the sensory-discriminative dimension of pain: a functional MRI study. *Eur J Neurosci* 2006; 23:1377–1383.
- 21 Coghill RC, Sang CN, Maisog JM, Iadarola MJ. Pain intensity processing within the human brain: a bilateral, distributed mechanism. *J Neurophysiol* 1999; 82:1934–1943.
- 22 Rainville P, Duncan GH, Price DD, *et al.* Pain affect encoded in human anterior cingulate but not somatosensory cortex. *Science* 1997; 277:968–971.
- 23 Hofbauer RK, Rainville P, Duncan GH, Bushnell MC. Cortical representation of the sensory dimension of pain. *J Neurophysiol* 2001; 86:402–411.
- 24 Price DD. Psychological and neural mechanisms of the affective dimension of pain. *Science* 2000; 288:1769–1772.
- 25 Sowards TV, Sowards MA. The medial pain system: neural representations of the motivational aspect of pain. *Brain Res Bull* 2002; 59:163–180.
- 26 Treede RD, Kenshalo DR, Gracely RH, Jones AK. The cortical representation of pain. *Pain* 1999; 79:105–111.
- 27 Vogt BA, Sikes RW. The medial pain system, cingulate cortex, and parallel processing of nociceptive information. *Prog Brain Res* 2000; 122:223–235.

- 28 Kuner R. Central mechanisms of pathological pain. *Nat Med* 2010; 16:1258–1266.
- 29 Woolf CJ, Salter MW. Neuronal plasticity: increasing the gain in pain. *Science* 2000; 288:1765–1769.
- 30 Seifert F, Jungfer I, Schmelz M, Maihofner C. Representation of UV-B-induced thermal and mechanical hyperalgesia in the human brain: a functional MRI study. *Hum Brain Mapp* 2008; 29:1327–1342.
- 31 Maihofner C, Handwerker HO. Differential coding of hyperalgesia in the human brain: a functional MRI study. *Neuroimage* 2005; 28:996–1006.
- 32 Lorenz J, Cross D, Minoshima S, *et al.* A unique representation of heat allodynia in the human brain. *Neuron* 2002; 35:383–393.
- 33 Lee MC, Zambreau L, Menon DK, Tracey I. Identifying brain activity specifically related to the maintenance and perceptual consequence of central sensitization in humans. *J Neurosci* 2008; 28:11642–11649.
- 34 Baliki MN, Chialvo DR, Geha PY, *et al.* Chronic pain and the emotional brain: specific brain activity associated with spontaneous fluctuations of intensity of chronic back pain. *J Neurosci* 2006; 26:12165–12173.
- 35 Borsook D, Moulton EA, Schmidt KF, Becerra LR. Neuroimaging revolutionizes therapeutic approaches to chronic pain. *Mol Pain* 2007; 3:25.
- 36 Petrovic P, Ingvar M, Stone-Elander S, *et al.* A PET activation study of dynamic mechanical allodynia in patients with mononeuropathy. *Pain* 1999; 83:459–470.
- 37 Witting N, Kupers RC, Svensson P, Jensen TS. A PET activation study of brush-evoked allodynia in patients with nerve injury pain. *Pain* 2006; 120:145–154.
- 38 Schweinhardt P, Glynn C, Brooks J, *et al.* An fMRI study of cerebral processing of brush-evoked allodynia in neuropathic pain patients. *Neuroimage* 2006; 32:256–265.
- 39 Becerra L, Morris S, Bazes S, *et al.* Trigeminal neuropathic pain alters responses in CNS circuits to mechanical (brush) and thermal (cold and heat) stimuli. *J Neurosci* 2006; 26:10646–10657.
- 40 Peyron R, Garcia-Larrea L, Gregoire MC, *et al.* Allodynia after lateral-medullary (Wallenberg) infarct. A PET study. *Brain* 1998; 121 (Pt 2): 345–356.
- 41 Ducreux D, Attal N, Parker F, Bouhassira D. Mechanisms of central neuropathic pain: a combined psychophysical and fMRI study in syringomyelia. *Brain* 2006; 129:963–976.
- 42 Maihofner C, Handwerker HO, Birklein F. Functional imaging of allodynia in complex regional pain syndrome. *Neurology* 2006; 66:711–717.
- 43 Maihofner C, Forster C, Birklein F, *et al.* Brain processing during mechanical hyperalgesia in complex regional pain syndrome: a functional MRI study. *Pain* 2005; 114:93–103.
- 44 Napadow V, Kettner N, Ryan A, *et al.* Somatosensory cortical plasticity in carpal tunnel syndrome: a cross-sectional fMRI evaluation. *Neuroimage* 2006; 31:520–530.
- 45 Tecchio F, Padua L, Aprile I, Rossini PM. Carpal tunnel syndrome modifies sensory hand cortical somatotopy: a MEG study. *Hum Brain Mapp* 2002; 17:28–36.
- 46 Flor H, Nikolajsen L, Staehelin Jensen T. Phantom limb pain: a case of maladaptive CNS plasticity? *Nat Rev Neurosci* 2006; 7:873–881.
- 47 Flor H. Phantom-limb pain: characteristics, causes, and treatment. *Lancet Neurol* 2002; 1:182–189.
- 48 Elbert T, Flor H, Birbaumer N, *et al.* Extensive reorganization of the somatosensory cortex in adult humans after nervous system injury. *Neuroreport* 1994; 5:2593–2597.
- 49 Flor H, Elbert T, Knecht S, *et al.* Phantom-limb pain as a perceptual correlate of cortical reorganization following arm amputation. *Nature* 1995; 375:482–484.
- 50 Yang TT, Gallen CC, Ramachandran VS, *et al.* Noninvasive detection of cerebral plasticity in adult human somatosensory cortex. *Neuroreport* 1994; 5:701–704.
- 51 Nikolajsen L, Ilkjaer S, Kroner K, *et al.* The influence of preamputation pain on postamputation stump and phantom pain. *Pain* 1997; 72:393–405.
- 52 Flor H, Denke C, Schaefer M, Grusser S. Effect of sensory discrimination training on cortical reorganisation and phantom limb pain. *Lancet* 2001; 357:1763–1764.
- 53 Lotze M, Grodd W, Birbaumer N, *et al.* Does use of a myoelectric prosthesis prevent cortical reorganization and phantom limb pain? *Nat Neurosci* 1999; 2:501–502.
- 54 Wrigley PJ, Press SR, Gustin SM, *et al.* Neuropathic pain and primary somatosensory cortex reorganization following spinal cord injury. *Pain* 2009; 141:52–59.
- 55 Henderson LA, Gustin SM, Macey PM, *et al.* Functional reorganization of the brain in humans following spinal cord injury: evidence for underlying changes in cortical anatomy. *J Neurosci* 2011; 31:2630–2637.
- S1 reorganization was demonstrated in SCI patients and the amount of reorganization correlated with ongoing pain intensity levels.
- 56 Maihofner C, Seifert F, Markovic K. Complex regional pain syndromes: new pathophysiological concepts and therapies. *Eur J Neurol* 2010; 17:649–660.
- 57 Maihofner C, Handwerker HO, Neundorfer B, Birklein F. Patterns of cortical reorganization in complex regional pain syndrome. *Neurology* 2003; 61:1707–1715.
- 58 Schwenkreis P, Janssen F, Rommel O, *et al.* Bilateral motor cortex disinhibition in complex regional pain syndrome (CRPS) type I of the hand. *Neurology* 2003; 61:515–519.
- 59 Maihofner C, Handwerker HO, Neundorfer B, Birklein F. Cortical reorganization during recovery from complex regional pain syndrome. *Neurology* 2004; 63:693–701.
- 60 Maihofner C, Neundorfer B, Birklein F, Handwerker HO. Mislocalization of tactile stimulation in patients with complex regional pain syndrome. *J Neurol* 2006; 253:772–779.
- 61 Pleger B, Tegenthoff M, Ragert P, *et al.* Sensorimotor retuning [corrected] in complex regional pain syndrome parallels pain reduction. *Ann Neurol* 2005; 57:425–429.
- 62 Maihofner C, Baron R, DeCol R, *et al.* The motor system shows adaptive changes in complex regional pain syndrome. *Brain* 2007; 130:2671–2687.
- 63 Rommel O, Gehling M, Dertwinkel R, *et al.* Hemisensory impairment in patients with complex regional pain syndrome. *Pain* 1999; 80:95–101.
- 64 Rommel O, Malin JP, Zenz M, Janig W. Quantitative sensory testing, neurophysiological and psychological examination in patients with complex regional pain syndrome and hemisensory deficits. *Pain* 2001; 93:279–293.
- 65 Schwartzman RJ, Kerrigan J. The movement disorder of reflex sympathetic dystrophy. *Neurology* 1990; 40:57–61.
- 66 Van Rijn MA, Marinus J, Putter H, van Hilten JJ. Onset and progression of dystonia in complex regional pain syndrome. *Pain* 2007; 130:287–293.
- 67 Frettlöh J, Huppe M, Maier C. Severity and specificity of neglect-like symptoms in patients with complex regional pain syndrome (CRPS) compared to chronic limb pain of other origins. *Pain* 2006; 124:184–189.
- 68 Juottonen K, Gockel M, Silen T, *et al.* Altered central sensorimotor processing in patients with complex regional pain syndrome. *Pain* 2002; 98:315–323.
- 69 Eisenberg E, Chistyakov AV, Yudashkin M, *et al.* Evidence for cortical hyperexcitability of the affected limb representation area in CRPS: a psychophysical and transcranial magnetic stimulation study. *Pain* 2005; 113:99–105.
- 70 Napadow V, Liu J, Li M, *et al.* Somatosensory cortical plasticity in carpal tunnel syndrome treated by acupuncture. *Hum Brain Mapp* 2007; 28:159–171.
- 71 Fox MD, Raichle ME. Spontaneous fluctuations in brain activity observed with functional magnetic resonance imaging. *Nat Rev Neurosci* 2007; 8:700–711.
- 72 Raichle ME. Neuroscience. The brain's dark energy. *Science* 2006; 314:1249–1250.
- 73 Raichle ME, MacLeod AM, Snyder AZ, *et al.* A default mode of brain function. *Proc Natl Acad Sci U S A* 2001; 98:676–682.
- 74 Zhang D, Raichle ME. Disease and the brain's dark energy. *Nat Rev Neurol* 2010; 6:15–28.
- 75 Cauda F, Sacco K, D'Agata F, *et al.* Low-frequency BOLD fluctuations demonstrate altered thalamocortical connectivity in diabetic neuropathic pain. *BMC Neurosci* 2009; 10:138.
- 76 Baliki MN, Geha PY, Fields HL, Apkarian AV. Predicting value of pain and analgesia: nucleus accumbens response to noxious stimuli changes in the presence of chronic pain. *Neuron* 2010; 66:149–160.
- This recent study of outstanding interest shows that nucleus accumbens activity in humans encodes the predicted value and anticipates the analgesic potential of noxious stimuli on chronic pain.
- 77 Ploner M, Lee MC, Wiech K, *et al.* Prestimulus functional connectivity determines pain perception in humans. *Proc Natl Acad Sci U S A* 2010; 107:355–360.
- The study shows that prestimulus connectivity among brain areas involved in pain processing determines whether a noxious event is perceived as painful.

- 78 Peltz E, Seifert F, Decol R, *et al.* Functional connectivity of the human insular cortex during noxious and innocuous thermal stimulation. *Neuroimage* 2010; 54:1324–1335.

This recent study used functional connectivity MRI during noxious stimulation to investigate stimulus-specific connectivity of the anterior and posterior insula. The anterior insula is more strongly functionally connected to areas known for affective and cognitive processing, whereas the posterior insula is more strongly connected with areas known for sensory-discriminative processing of noxious and somatosensory stimuli.

- 79 Apkarian AV, Sosa Y, Sonty S, *et al.* Chronic back pain is associated with decreased prefrontal and thalamic gray matter density. *J Neurosci* 2004; 24:10410–10415.
- 80 Draganski B, Moser T, Lummel N, *et al.* Decrease of thalamic gray matter following limb amputation. *Neuroimage* 2006; 31:951–957.
- 81 Geha PY, Baliki MN, Harden RN, *et al.* The brain in chronic CRPS pain: abnormal gray-white matter interactions in emotional and autonomic regions. *Neuron* 2008; 60:570–581.
- 82 Gustin SM, Wrigley PJ, Siddall PJ, Henderson LA. Brain anatomy changes associated with persistent neuropathic pain following spinal cord injury. *Cereb Cortex* 2010; 20:1409–1419.
- 83 Kim JH, Suh SI, Seol HY, *et al.* Regional grey matter changes in patients with migraine: a voxel-based morphometry study. *Cephalalgia* 2008; 28:598–604.
- 84 Rocca MA, Ceccarelli A, Falini A, *et al.* Brain gray matter changes in migraine patients with T2-visible lesions: a 3-T MRI study. *Stroke* 2006; 37:1765–1770.
- 85 Schmidt-Wilcke T, Ganssbauer S, Neuner T, *et al.* Subtle grey matter changes between migraine patients and healthy controls. *Cephalalgia* 2008; 28:1–4.
- 86 Valfre W, Rainero I, Bergui M, Pinessi L. Voxel-based morphometry reveals gray matter abnormalities in migraine. *Headache* 2008; 48:109–117.
- 87 Schmitz N, Admiraal-Behloul F, Arkink EB, *et al.* Attack frequency and disease duration as indicators for brain damage in migraine. *Headache* 2008; 48:1044–1055.
- 88 Vartiainen N, Kallio-Laine K, Hlushchuk Y, *et al.* Changes in brain function and morphology in patients with recurring herpes simplex virus infections and chronic pain. *Pain* 2009; 144:200–208.
- 89 Rodriguez-Raecke R, Niemeier A, Ihle K, *et al.* Brain gray matter decrease in chronic pain is the consequence and not the cause of pain. *J Neurosci* 2009; 29:13746–13750.
- 90 Gwilym SE, Filippini N, Douaud G, *et al.* Thalamic atrophy associated with painful osteoarthritis of the hip is reversible after arthroplasty: a longitudinal voxel-based morphometric study. *Arthritis Rheum* 2010; 62:2930–2940.
- 91 Porreca F, Ossipov MH, Gebhart GF. Chronic pain and medullary descending facilitation. *Trends Neurosci* 2002; 25:319–325.
- 92 Bantick SJ, Wise RG, Ploghaus A, *et al.* Imaging how attention modulates pain in humans using functional MRI. *Brain* 2002; 125:310–319.
- 93 Tracey I, Ploghaus A, Gati JS, *et al.* Imaging attentional modulation of pain in the periaqueductal gray in humans. *J Neurosci* 2002; 22:2748–2752.

- 94 Valet M, Sprenger T, Boecker H, *et al.* Distraction modulates connectivity of the cingulo-frontal cortex and the midbrain during pain—an fMRI analysis. *Pain* 2004; 109:399–408.
- 95 Petrovic P, Kalso E, Petersson KM, Ingvar M. Placebo and opioid analgesia: imaging a shared neuronal network. *Science* 2002; 295:1737–1740.
- 96 Zubieta JK, Bueller JA, Jackson LR, *et al.* Placebo effects mediated by endogenous opioid activity on mu-opioid receptors. *J Neurosci* 2005; 25:7754–7762.
- 97 Bingel U, Lorenz J, Schoell E, *et al.* Mechanisms of placebo analgesia: rACC recruitment of a subcortical antinociceptive network. *Pain* 2006; 120:8–15.
- 98 Hsieh JC, Stone-Elender S, Ingvar M. Anticipatory coping of pain expressed in the human anterior cingulate cortex: a positron emission tomography study. *Neurosci Lett* 1999; 262:61–64.
- 99 Ploghaus A, Tracey I, Gati JS, *et al.* Dissociating pain from its anticipation in the human brain. *Science* 1999; 284:1979–1981.
- 100 Porro CA, Baraldi P, Pagnoni G, *et al.* Does anticipation of pain affect cortical nociceptive systems? *J Neurosci* 2002; 22:3206–3214.
- 101 Porro CA, Cettolo V, Francescato MP, Baraldi P. Functional activity mapping of the mesial hemispheric wall during anticipation of pain. *Neuroimage* 2003; 19:1738–1747.
- 102 Ploghaus A, Narain C, Beckmann CF, *et al.* Exacerbation of pain by anxiety is associated with activity in a hippocampal network. *J Neurosci* 2001; 21:9896–9903.
- 103 Bingel U, Tracey I. Imaging CNS modulation of pain in humans. *Physiology (Bethesda)* 2008; 23:371–380.
- 104 Bingel U, Schoell E, Buchel C. Imaging pain modulation in health and disease. *Curr Opin Neurol* 2007; 20:424–431.
- 105 Moulton EA, Burstein R, Tully S, *et al.* Interictal dysfunction of a brainstem descending modulatory center in migraine patients. *PLoS One* 2008; 3:e3799.
- 106 Seifert F, Kiefer G, DeCol R, *et al.* Differential endogenous pain modulation in complex-regional pain syndrome. *Brain* 2009; 132:788–800.
- 107 Edwards RR. Individual differences in endogenous pain modulation as a risk factor for chronic pain. *Neurology* 2005; 65:437–443.
- 108 Haynes JD, Rees G. Decoding mental states from brain activity in humans. *Nat Rev Neurosci* 2006; 7:523–534.
- 109 Richiardi J, Eryilmaz H, Schwartz S, *et al.* Decoding brain states from fMRI connectivity graphs. *Neuroimage* 2011; 56:616–626.
- 110 Iannetti GD, Zambreanu L, Wise RG, *et al.* Pharmacological modulation of pain-related brain activity during normal and central sensitization states in humans. *Proc Natl Acad Sci U S A* 2005; 102:18195–18200.
- 111 Maihofner C, Ringler R, Herrndobler F, Koppert W. Brain imaging of analgesic and antihyperalgesic effects of cyclooxygenase inhibition in an experimental human pain model: a functional MRI study. *Eur J Neurosci* 2007; 26:1344–1356.
- 112 Seifert F, Bschorer K, De Col R, *et al.* Medial prefrontal cortex activity is predictive for hyperalgesia and pharmacological antihyperalgesia. *J Neurosci* 2009; 29:6167–6175.